

# Clinical Practice Guideline for Foot and Ankle Diagnosis and Treatment

## TABLE OF CONTENTS

<b>I. Review Criteria for Foot and Ankle Surgery .....</b>	<b>3</b>
<b>II. Introduction .....</b>	<b>12</b>
A. Background and Prevalence .....	12
<b>III. Establishing Work-relatedness.....</b>	<b>14</b>
<b>IV. Pre-existing Non-work-related Conditions .....</b>	<b>14</b>
A. Pes Planus .....	14
B. Pes Cavus .....	15
C. Plantar Fasciitis .....	16
D. Osteoarthritis.....	16
<b>V. Assessment .....</b>	<b>17</b>
A. Imaging.....	17
B. Preventing Complications .....	18
C. Measuring Functional Improvement .....	18
<b>VI. Specific Conditions and Surgical Procedures.....</b>	<b>19</b>
A. Ankle Arthroscopy and Cheilectomy .....	19
B. Ankle Arthrodesis/Fusion or Arthroplasty/Replacement .....	19
Arthrodesis/Fusion .....	20
Arthroplasty/Joint Replacement .....	20
C. Subtalar Arthrodesis .....	20
D. Debridement or Stabilization of a Medial or Lateral Talar Lesion.....	21
E. Lateral Ligament Repair or Reconstruction .....	22
F. Peroneal Tendon Repair .....	22
G. Achilles Tendon Repair or Reconstruction.....	22



Repair at Insertion .....	23
Repair.....	23
Reconstruction.....	23
H. Posterior Tibialis Tendon Reconstruction.....	23
PTTD and Work-relatedness.....	24
I. Tarsal Tunnel Release .....	24
J. Amputations.....	25
Amputations Contemplated in the Setting of Chronic Pain .....	25
<b>VII. Return to Work .....</b>	<b>26</b>
<b>VIII. Acknowledgements .....</b>	<b>27</b>
<b>IX. References .....</b>	<b>28</b>

## I. Review Criteria for Foot and Ankle Surgery

**Note: Not all surgical procedures that require prior authorization appear in this criteria table.**

A request may be appropriate for	If the patient has	AND the diagnosis is supported by these clinical findings:			AND this has been done
		Subjective	Objective	Imaging	Non-operative care
Ankle Arthroscopy	Loose body	A discrete documented work-related ankle injury	Catching <b>AND/OR</b> Locking <b>AND/OR</b> Effusion	Documented loose body on computed tomography (CT) or magnetic resonance imaging (MRI)	Not required
Ankle Cheilectomy	Bony impingement	A discrete documented work-related ankle injury  <b>AND</b> Pain	Decrease in range of motion (ROM)	Plain radiographs demonstrating osteophyte formation on the distal tibia or talus	At least 6 weeks of any of the following:  Activity modification, Non-opioid analgesics, Steroid injection, Bracing
Ankle Arthroplasty or Ankle Fusion	Arthrosis due to post-traumatic arthritis from a previous work-related injury	A discrete documented work-related ankle injury  <b>AND</b> Pain	Visual or radiographic deformity <b>AND/OR</b> Decreased range of motion (ROM)  Note: The nature/form of the deformity should be documented	Weight bearing plain films of the ankle reveal bone-on-bone arthrosis (e.g. severe loss of joint space) on at least one view	At least 6 weeks of any of the following:  Activity modification, Non-opioid analgesics, Bracing



A request may be appropriate for	If the patient has	AND the diagnosis is supported by these clinical findings:			AND this has been done
Surgical Procedure	Condition or Diagnosis	Subjective	Objective	Imaging	Non-operative care
Double Arthrodesis Subtalar Arthrodesis Triple Arthrodesis Calcaneal Cuboid Arthrodesis Gastroc Slide/ Tendon Achilles Lengthening (TAL)	Post-traumatic arthritis of the hindfoot resulting from a previous work-related injury	A discrete documented work-related injury, that results in post-traumatic arthritis of the hindfoot  <b>AND</b>  Pain  *Congenital hindfoot valgus and pes planus, if present, do not arise from and are not worsened by cumulative weight bearing in the workplace	Swelling  <b>AND/OR</b> Decreased ROM	Weight bearing x-ray reveals joint space narrowing, must be confirmed by CT	At least 12 weeks of any of the following:  Activity modification, Non-opioid analgesics, Bracing, Immobilization, Orthotics, Injections

A request may be appropriate for	If the patient has	AND the diagnosis is supported by these clinical findings:			AND this has been done
Surgical Procedure	Condition or Diagnosis	Subjective	Objective	Imaging	Non-operative care
Debridement or Stabilization of a <u>Medial</u> Lesion of the Talus	Osteochondral defect of the talus	A discrete documented work-related ankle injury  Pain  <b>AND</b>	Diagnostic lidocaine injection* demonstrates > 50 % pain relief and at least 3 point improvement on visual analog scale *Use contrast and fluoroscopy to confirm placement in the joint <u>Positive</u> results indicate pain originates within the joint <u>Negative</u> result is an indicator NOT to perform surgery	MRI demonstrates bone marrow edema associated with a focal lesion  <b>OR</b> CT scan demonstrates an osteochondral defect	At least 6 weeks of any of the following: Activity modification, Non-opioid analgesics, Bracing *Non-operative management is not required if a detached fragment is present
Debridement or Stabilization of a <u>Lateral</u> Lesion of the Talus	Osteochondral defect of the talus	A discrete documented work-related ankle injury  Pain  <b>AND</b>	There are no physical findings that are pathognomonic of osteochondral lesions	MRI demonstrates bone marrow edema associated with a focal lesion  <b>OR</b> CT scan demonstrates an osteochondral defect	At least 6 weeks of any of the following: Activity modification, Non-opioid analgesics, Bracing *Non-operative management is not required if a detached fragment is present

A request may be appropriate for	If the patient has	AND the diagnosis is supported by these clinical findings:			AND this has been done
Surgical Procedure	Condition or Diagnosis	Subjective	Objective	Imaging	Non-operative care
Lateral Ankle Ligament Repair/ Reconstruction  e.g. Bröstrom procedure, Watson-Jones procedure	Severe ankle sprain or recurrent sprains leading to instability	A discrete documented work-related ankle injury  <b>AND</b> Ankle “gives way”  <b>OR</b> Swelling  <b>OR</b> Difficulty walking on uneven ground	Positive instability testing: e.g. Anterior drawer testing  <b>OR</b> Asymmetric inversion laxity (when compared to contralateral side)	Bilateral stress X-rays w/ asymmetrical stress tests: Talar tilt > 10 degrees  <b>OR</b> Anterior displacement index of >15%  *MRI may be useful to more specifically diagnose possible underlying pathology	At least three months of conservative care which may include:  Physical Therapy, Bracing, Casting, Taping, Immobilization

A request may be appropriate for	If the patient has	AND the diagnosis is supported by these clinical findings:			AND this has been done
Surgical Procedure	Condition or Diagnosis	Subjective	Objective	Imaging	Non-operative care
<p>Peroneal Tendon Reconstruction</p> <p>If underlying deformities require correction, these procedures may be medically necessary: calcaneal osteotomy, medial midfoot osteotomy, medial column osteotomy</p>	<p>Tenosynovitis, tear, rupture, or dislocation of the peroneal tendon(s)</p> <p><b>OR</b></p> <p>Os peroneum fracture or contusion</p>	<p>A discrete documented work-related ankle injury</p> <p><b>AND</b></p> <p>Lateral ankle/foot pain</p> <p><b>AND/OR</b></p> <p>Swelling</p> <p><b>AND/OR</b></p> <p>Popping</p>	<p>Clinical examination is anatomically consistent with MRI findings</p> <p>Dislocating peroneal tendon</p> <p><b>AND/OR</b></p> <p>Weakness to eversion or dorsiflexion</p> <p><b>AND/OR</b></p> <p>Effusion</p> <p>If there are documented underlying deformities present that could cause failure of reconstruction, they should be corrected at time of surgery</p>	<p>MRI demonstrates a longitudinal/partial thickness tear, dislocation, or pathologic anatomy consistent with a dislocation of the peroneal tendon(s)</p> <p><b>OR</b></p> <p>Plain X-Ray demonstrates os peroneum fracture</p>	<p>Dislocating or rupture of the tendon(s) does not require non-operative care</p> <p>Longitudinal/partial thickness tears, or tenosynovitis:</p> <p>At least 12 weeks of a combination of the following:</p> <p>Activity modification, Non-opioid analgesics, Bracing, Immobilization</p>

A request may be appropriate for	If the patient has	AND the diagnosis is supported by these clinical findings:			AND this has been done
		Subjective	Objective	Imaging	
Surgical Procedure	Condition or Diagnosis				Non-operative care
Achilles Tendon Repair	An acute complete tear/rupture of the Achilles tendon	A discrete documented work-related ankle injury  <b>AND</b> Pain  <b>AND/OR</b> Plantarflexion weakness	Positive Thompson's test  <b>AND/OR</b> Palpable defect  <b>AND/OR</b> Swelling  <b>AND/OR</b> Plantarflexion weakness	Not required  *If an MRI has been obtained, must reveal complete rupture of the Achilles tendon	Non-operative care is not required
Achilles Tendon Reconstruction	Sub-acute/chronic Achilles tendon tear/rupture (When diagnosis is made >4 weeks post-injury)	A discrete documented work-related ankle injury  <b>AND</b> Pain  <b>AND/OR</b> Plantarflexion weakness	Positive Thompson's test  <b>AND/OR</b> Plantarflexion weakness  <b>AND/OR</b> Achilles tendon laxity	MRI demonstrates heterogeneous signal intensity consistent with a chronic tear	Non-operative care is not required



A request may be appropriate for	If the patient has	AND the diagnosis is supported by these clinical findings:			AND this has been done
		Subjective	Objective	Imaging	
Surgical Procedure	Condition or Diagnosis				Non-operative care
Insertional Achilles Tendon Reconstruction Osteotomy Flexor Hallucis Longus Transfer Gastroc Slide	Insertional Achilles tendinopathy, with or without Haglund deformity	A discrete documented work-related injury from either singular direct trauma, or repetitive traumatic exposure, or acute strain to the insertion of the Achilles tendon  <b>AND</b> Pain	Pain with palpation  <b>OR</b> Swelling  <b>OR</b> Warmth/redness	MRI demonstrates abnormal signal in the bone, bursa, or tendon	At least 12 weeks of any of the following:  Activity modification Non-opioid analgesics, Bracing Immobilization
Posterior Tibialis Tendon Reconstruction Medializing Calcaneal Osteotomy Spring Ligament Reconstruction Gastroc Slide FDL Transfer Subtalar Fusion Triple Arthrodesis	Posterior tibialis tendon insufficiency/dysfunction  Spring ligament sprain or rupture  Hindfoot/midfoot deformity and post-traumatic arthritis	A discrete documented work-related injury, the mechanism of which transmits enough force to cause insufficiency of the posterior tibial tendon, or sprain or rupture of the spring ligament.  <b>AND</b> Medial ankle or mid-foot pain  In the patient with congenital hindfoot	Swelling  <b>AND</b> One of the following: Inability to do a single foot heel rise  <b>AND/OR</b> Asymmetric pes planus with heel valgus and the too-many-toes sign	MRI demonstrates posterior tibial tendinopathy/tenosynovitis  <b>AND/OR</b> Spring ligament tear	At least 12 weeks of any of the following:  Activity modification Non-opioid analgesics Bracing Immobilization Orthotics

*Continued next page*

A request may be appropriate for	If the patient has	AND the diagnosis is supported by these clinical findings:			AND this has been done
		Subjective	Objective	Imaging	Non-operative care
Surgical Procedure	Condition or Diagnosis				
Medial Cuneiform Osteotomy Lateral Column Lengthening Kidner Procedure		valgus and pes planus posture of the foot, this condition does not arise from and is not worsened by cumulative weight bearing in the workplace			
Tarsal Tunnel Release	Tarsal tunnel syndrome (TTS)	A discrete documented work-related foot/ankle injury  <b>AND</b> Pain/paresthesias in the distribution of the medial and/or lateral plantar nerves	If a compressive lesion is not present on MRI, a positive nerve conduction study (NCS) consistent with tarsal tunnel syndrome*  *NCSs of this nerve are typically difficult to perform and interpret	A MRI is required for all surgical candidates; <b>AND</b> A compressive lesion is seen on the MRI affecting the tibial nerve (e.g. cyst)  * An MRI demonstrates a compressive lesion affecting the tibial nerve OR if there is no evidence of a compressive lesion, a positive NCS consistent with tarsal tunnel syndrome	6 weeks of non-operative care UNLESS MRI shows space occupying lesion



A request may be appropriate for	If the patient has	AND the diagnosis is supported by these clinical findings:			AND this has been done
Surgical Procedure	Condition or Diagnosis	Subjective	Objective	Imaging	Non-operative care
Elective Amputation when pain is the primary indication	If amputation is being requested, after all conservative care efforts have been exhausted, the patient must be evaluated at a Department of Labor and Industries designated amputation Center of Excellence. See <a href="#">Amputations Contemplated in the Setting of Chronic Pain</a> for further discussion.				

## II. Introduction

This guideline reflects a best practice standard for surgical treatment of certain foot and ankle conditions sustained by injured workers treated in the Washington State workers' compensation system under Title 51 Revised Code of Washington (RCW). Providers who are in the department's Medical Provider Network are required to follow this guideline when treating injured workers.<sup>a</sup> The surgical criteria are used in the department's utilization review program as the supporting evidence has shown these provide the best chance for injured workers to have a good surgical outcome. To help ensure that diagnosis and treatment of foot and ankle conditions are of the highest quality, this guideline emphasizes:

- Conducting a thorough assessment and making an accurate diagnosis.
- Appropriately determining work-relatedness.
- Making the best treatment decisions that are curative or rehabilitative.<sup>b</sup>
- Facilitating the worker's return to health, productivity, and work.

The guideline was developed in 2016-2017 by a subcommittee of the Industrial Insurance Medical Advisory Committee (IIMAC). The subcommittee was comprised of practicing physicians in rehabilitation medicine, occupational medicine, orthopedic surgery, and podiatry. The guideline recommendations are based on the weight of the best available clinical and scientific evidence from a systematic review of medical literature, and on a consensus of expert opinion when scientific evidence was insufficient or inconclusive. Visit the department's [Medical Treatment Guidelines](#) webpage for detailed information on the guideline development process.<sup>c</sup>

### A. Background and Prevalence

Workplace accidents (such as falls, slips, and machinery entrapment), that result in traumatic foot and ankle injuries (such as fractures, sprains, and crush injuries or amputations), are the most recognizable. At the same time, non-work related congenital problems (e.g. flat feet), joint instability (such as from an old sport injury), and chronic conditions (e.g. diabetic peripheral neuropathy) can predispose a person to being injured on the job and can complicate recovery. The goal after a workplace injury is to return the worker to as close to pre-injury status as possible and maximize function and the ability to return to work.

The Bureau of Labor Statistics reports that the incidence rate for injuries to the ankle is 5.6 per 10,000 full time workers, and the incidence rate for foot injuries as 4.8 per 10,000 full time workers.<sup>1</sup> Sprains, strains, and tears in the ankle were the injury type with the highest incidence at 3.7 per 10,000 full time workers. Most of these injuries are first treated in hospital emergency departments. One study found the estimated incidence of ankle sprains or strains was 206 per 100,000 patients reporting to an emergency department.<sup>2</sup> In the same study, the estimated incidence of ankle fractures was 49 per 100,000 reporting, and for foot contusions or abrasions, the estimated incidence was 50 per 100,000 reporting.

---

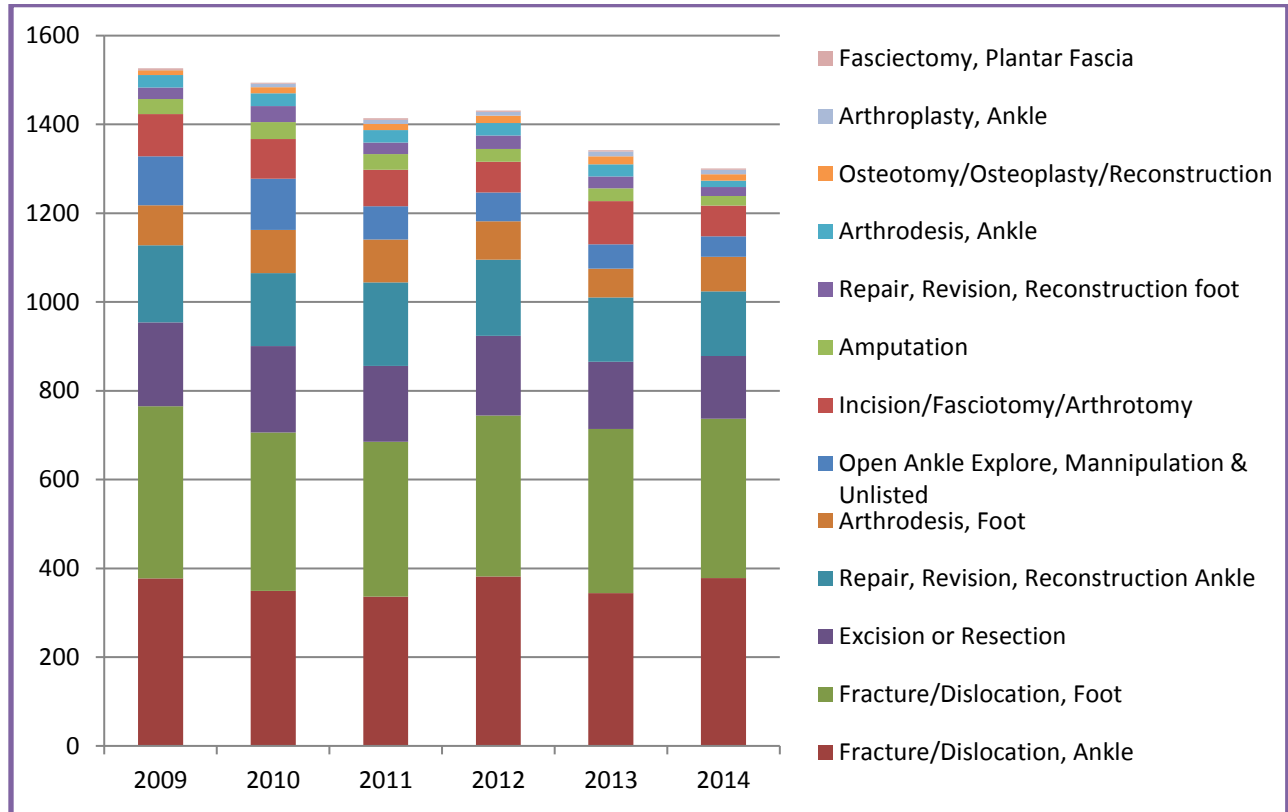
<sup>a</sup> <http://app.leg.wa.gov/RCW/default.aspx?cite=51.36.010>

<sup>b</sup> <http://app.leg.wa.gov/wac/default.aspx?cite=296-20-01002>

<sup>c</sup> <http://www.lni.wa.gov/ClaimsIns/Providers/TreatingPatients/TreatGuide/?F=MainFooter&source=FF>

The incidence of foot and ankle surgeries in Washington State’s workers’ compensation system is remarkably consistent across each year and category (Figure 1).

**Figure A. Number and Distribution of foot/ankle surgeries 2009-2014**



**Figure B: Surgery Rates**

WA Workers’ Compensation  
Paid Foot/ankle Surgeries 2009-2014

- 6756 workers had at least one surgery in the foot and/or ankle
- 42% fractures and dislocations
- 10% excision or resection, e.g. lesions, spurs, bone, tumor, etc.
- 10% repair, revision, reconstruction of ankle (without fracture)
- 2% amputation procedures
- Multiple surgery distribution:
  - 1 surgery: 56%
  - 2 surgeries: 26%
  - 3 surgeries: 11%
  - 4 surgeries: 4%
  - 5 or more surgeries: all ≤ 2%

### III. Establishing Work-relatedness

An injury sustained during the course of employment is defined in Washington State statute as “a sudden and tangible happening, of a traumatic nature, producing an immediate or prompt result, and occurring from without, and such physical conditions as result therefrom.”<sup>d</sup> A legal test for whether the department or self-insured employer is liable for the care that a worker receives for an injury is whether the workplace injury is “a proximate cause” of the accepted condition being treated. An injury may be a proximate cause of a condition being treated only if “but for” the injury, the treatment would not be necessary and proper. One approach to determining whether an injury meets this test is to determine whether the worker’s need for treatment is any different than it would have been had, the work-related injury never occurred. In the case of degenerative conditions, consider whether the duties and tasks of the job significantly contributed to aggravation of the condition beyond what would normally be expected for the worker’s age and genetics. If the answer is no, then it is likely not work related. If a proposed treatment would have been needed regardless of the industrial injury, the injury would not be a proximate cause of the need for treatment.

Occupational disease is defined in RCW 51.08.140 as a “disease or infection that arises naturally and proximately out of employment.”<sup>e</sup> Establishing an occupational disease diagnosis requires that all of the following criteria be met:

1. **Exposure:** Workplace activities that contribute to or cause foot or ankle conditions, **and**
2. **Outcome:** Diagnosis of a condition that meets the diagnostic criteria in this guideline, **and**
3. **Relationship:** Documentation that based on generally accepted scientific evidence, the work exposures created a risk of contracting or worsening the condition relative to the risks in everyday life, on a more-probable-than-not basis (*Dennis v. Dept. of Labor and Industries*, 1987). In epidemiological studies, this will usually translate to an Odds Ratio (OR)  $\geq 2$ .

A thorough occupational and non-occupational exposure history is essential for determining whether a condition is work-related and whether it is due to an acute or chronic exposure. For chronic exposures, it is important to document where, when, and for how long they occurred, as they could span multiple employers who would then share liability for an occupational disease. Providers should submit the [Occupational Disease and Employment History](#) form to the department or self-insurer as soon as possible (a second form must be used for [continuation of the occupational disease history](#)).<sup>f</sup>

## IV. Pre-existing Non-work-related Conditions

### A. Pes Planus

Pes planus, also known as flat feet or fallen arches, is a foot condition characterized by a flattened, pronated foot in the subtalar neutral position.<sup>3</sup> In general, humans are born with flat feet, and the medial

<sup>d</sup> <http://app.leg.wa.gov/RCW/default.aspx?cite=51.08.100>

<sup>e</sup> <http://app.leg.wa.gov/RCW/default.aspx?cite=51.08.140>

<sup>f</sup> <http://www.lni.wa.gov/Forms/pdf/F242-071-000.pdf>; <http://www.lni.wa.gov/Forms/pdf/F242-071-111.pdf>

arch of the foot typically develops during the first decade of life.<sup>4</sup> In some cases, an absent or abnormally low arch persists through adolescence, or is acquired in adulthood.<sup>5</sup>

Classification of pes planus generally refers to flexible or rigid varieties, characterized by a qualitative assessment of the stiffness of the foot during dynamic loading and/or physical exam.<sup>6</sup> Flexible pes planus is usually considered a continuation of a congenital condition, is generally asymptomatic, and can resolve with time.<sup>4</sup> In some cases, the condition is symptomatic and pathological, and may require treatment.<sup>4</sup> When treatment is required, conservative interventions have been shown to help manage the condition,<sup>7</sup> though surgical intervention may be necessary if conservative options fail.<sup>8,9</sup>

Acquired pes planus is often asymptomatic and is characterized by an abducted forefoot and valgus hindfoot.<sup>10</sup> Acquired pes planus has been attributed to inflammatory arthritis, trauma, and most commonly posterior tibial tendon dysfunction (PTTD).<sup>11,12</sup> PTTD will be addressed later in the guideline within the [posterior tibialis tendon reconstruction](#) section.

Pes planus may predispose a worker to having foot pain if his or her job involves prolonged periods of weight bearing. While an association between prolonged standing and increased risks of musculoskeletal pain has been shown, there is insufficient evidence to demonstrate that prolonged weight bearing is associated with pes planus.<sup>13</sup>

## B. Pes Cavus

Pes cavus refers to a foot deformity in which the medial longitudinal arch of the foot is abnormally high and does not flatten with weight bearing.<sup>14</sup> Gait deficits and foot pain have been associated with pes cavus resulting from the decreased ability to absorb ground reaction forces due to the characteristic shape of a cavus foot.<sup>14</sup> Presenting in either childhood or adulthood, a cavus foot is a relatively common finding, occurring in one fifth to one quarter of the general population.<sup>15</sup> Several primary origins have been associated with pes cavus: neuromuscular, congenital, idiopathic, and traumatic.<sup>14,16</sup> Neurological conditions such as cerebral palsy, muscular dystrophy, Charcot-Marie-Tooth disease, and poliomyelitis account for 75% of all pes cavus cases.<sup>16</sup> As such, pes cavus is not considered a work-related condition.

Symptoms of pes cavus can include recurrent ankle sprain, tendon disorders, instability in gait, callous formation and stress fractures to the lateral border of the foot.<sup>14,16-19</sup> This type of symptomology is thought to derive from abnormal pressure distribution across the sole of the foot and can contribute to significant disability.<sup>14,20</sup> The presence of this type of variant foot mechanics could predispose a worker to mechanical stresses that may contribute to foot complaints. Treatment of pes cavus is primarily conservative, with orthotics commonly used to reduce and redistribute pressure on the sole of the foot.<sup>14</sup> Additional conservative treatment methods include balance improvement, stretching and strengthening of weak muscles.<sup>19</sup> When conservative measures fail, surgical treatment may be required.<sup>21</sup>

## C. Plantar Fasciitis

The plantar fascia is a broad, fibrous tissue band that extends from the heel bone (calcaneus) to the toes (metatarsals), providing support to the arch and stabilizing it during normal weight bearing. Plantar fasciitis often presents as progressive and persistent deep, dull ache-like pain on the plantar surface of the heel. Other symptoms can include a burning sensation, pain and/or stiffness when getting out of bed, pain when getting up to walk after a period of inactivity, pain toward the end of the day, increased pain in the heel or arch, and overall tired feet.<sup>22-24</sup>

Acute trauma (e.g. jumping or falling from a high perch onto a hard surface) may injure or rupture the plantar fascia and could possibly be associated with occupational-related plantar fasciitis.<sup>25</sup> However, the evidence base suggesting associations of other, more chronic occupational exposures and the onset of occupational-related plantar fasciitis is unclear. Examples of potential chronic occupational exposures include long periods of standing or walking on certain surfaces (e.g. cement floors),<sup>22, 25, 26</sup> wearing non-supportive footwear,<sup>27-29</sup> or prolonged stressful activity (e.g. long distance running or unusual rapid walking such as a “forced march”).<sup>29</sup> The diagnosis of occupational-related plantar fasciitis thus remains controversial, and data are insufficient at this time to determine the risk posed by some specific chronic occupational exposures. Allowance of occupational-related plantar fasciitis would usually only be considered when the exposure is acute and related to significant occupational-related trauma to the heel or planter fascia.

Treatment of plantar fasciitis may include orthotics (pads), heel cord stretching exercises, anti-inflammatory medication, activity modification, night splinting, steroid injection to the site, or surgery.<sup>23, 30</sup> Surgical treatment (e.g. fasciotomy) is rarely indicated, with less than 5% of patients undergoing surgery.<sup>31</sup>

## D. Osteoarthritis

A complicating factor when trying to establish work-relatedness is the presence of osteoarthritis (OA). Osteoarthritis is a normal degenerative process and a progressive condition that results from loss or deterioration of articular cartilage. It is the most common arthritic disease, it is the most common cause of long-term disability in persons older than 65, and it is expected to become the world’s 4<sup>th</sup> leading cause of disability by 2020.<sup>32</sup>

While osteoarthritis is an important consideration for treatment of foot and ankle conditions, the ankle joint is much less likely to experience symptomatic OA through normal risk factors alone, such as age.<sup>33</sup> Brown et al estimated that nearly 80% of all ankle osteoarthritis is post-traumatic; and the estimated yearly incidence of symptomatic ankle OA in the same study was 1,113 cases in Iowa alone.<sup>34</sup> In patients seeking treatment, symptomatic osteoarthritis with radiographic changes occurs about 8-9.4 times more often in knee than in the ankle.<sup>35, 36</sup>



Therefore, in the vast majority of arthritic conditions attributed to an occupation, a substantial, discrete work-related traumatic event can be identified. A contention that an industrial injury caused, aggravated, or accelerated an osteoarthritic condition should be supported by adequate documentation, to include:

1. A careful prior medical history, and a careful history of the present condition, to document as clearly as possible any pre- or post-injury presence or progression, objectively or subjectively, of an osteoarthritic condition;
2. An evidence-based explanation supporting the contention that the osteoarthritis would not presently require treatment had the industrial injury or occupational disease not have occurred.

## V. Assessment

With 33 joints, 26 bones, and over 100 muscles, tendons, and ligaments, the foot and ankle are a complex structure. Clinical assessment should include:

- Observing the foot and ankle for shape, swelling/edema, and color.
- Checking the skin temperature.
- Palpating for tenderness, knowing that assessing for bony injury may be limited in acute injuries due to bruising and diffuse soft tissue swelling.
- Evaluating range of motion and weight bearing ability.
- Observing the workers gait and stance.
- Checking posterior, anterior, medial, and lateral angles for anatomical alignment and position of trunk and hip, hip and knee, knee and foot, and arch position.
- Condition-specific tests such as Thompson, Squeeze, External Rotation Stress, Anterior Drawer, and the Talar Tilt test.<sup>37</sup>

In addition to performing a thorough exam, it is critical to get an accurate history of injury occurrence, previous injuries, and underlying comorbidities/ risk factors, which may predispose the worker to further foot and ankle injury.

### A. Imaging

The recommended imaging procedures for various foot and ankle surgeries are specified in the criteria table. Weight bearing x-rays are recommended when determining the presence or extent of degenerative disease. Given the complex three dimensional anatomy of the foot and ankle, CT scans or CT-SPECT scans are used at times when finer detail is needed e.g. when suspecting an occult fracture or to further study characteristics of a known fracture, deformity, or arthritis. Magnetic resonance imaging (MRI) is most commonly used to diagnose injuries to the ligaments or tendons but is not recommended for every case of acute pain or for degenerative joint disease (L&I requires prior authorization for all MRIs; visit the [Advanced Imaging Guidelines](#) web page for complete information).<sup>8</sup>

---

<sup>8</sup> <http://www.lni.wa.gov/ClaimsIns/Providers/TreatingPatients/TreatGuide/imaging.asp>

## B. Preventing Complications

Worsening conditions can lead to treatment that is more drastic and even amputation, especially if careful monitoring and timely assessment and care are not done. It is critical to conduct a thorough assessment of risk factors prior to surgery to evaluate the risks and benefits of the procedure. Risk factors include:

- vascular disease
- diabetes and the extent of diabetic complications
- tobacco use
- age-related system changes such as immune status
- degree of soft tissue trauma and swelling
- expected duration of surgical time
- mental health status
- psychosocial status

Examples of this workup include determining the level of diabetic control through HbA1c values, performing appropriate vascular studies, consulting with a vascular surgeon, and initiating a preoperative [tobacco cessation program](#).<sup>h</sup>

Refer to the “[Conservative Care Options for Work-Related Foot and Ankle Conditions](#)” occupational health practice resource published by the Industrial Insurance Chiropractic Advisory Committee and Labor & Industries Office of the Medical Director for a thorough discussion of patient presentation, prognostic indicators, and clinical examination recommendations.<sup>i</sup>

## C. Measuring Functional Improvement

From the time of injury to full restoration, from conservative care to post-operative assessment, it’s critical to measure the patient’s functional improvement and changes in their pain experience using validated tools in a consistent fashion. Regular assessment not only helps to guide appropriate care, it helps prevent and/or identify risk factors and symptoms for developing [Complex Regional Pain Syndrome \(CRPS\)](#), which can be particularly difficult to treat.<sup>j</sup> The authors of this guideline recommend using the following validated tools for measuring pain and functional improvement:

The [Foot and Ankle Ability Measure](#) (FAAM) is a validated tool used to assess functional measure related to musculoskeletal disorders of the lower leg, foot, and ankle.<sup>38 k</sup>

---

<sup>h</sup> <http://www.lni.wa.gov/ClaimsIns/Providers/TreatingPatients/ByCondition/TobaccoCessation.asp>

<sup>i</sup> <http://www.lni.wa.gov/ClaimsIns/Files/OMD/IICAC/2015WorkRelatedMechanicalFootAnkleConditions44.pdf>

<sup>j</sup> <http://www.lni.wa.gov/ClaimsIns/Files/OMD/MedTreat/ComplexRegionalPain2011.pdf>

<sup>k</sup> <http://www.aaos.org/uploadedFiles/PreProduction/Quality/Measures/Foot%20and%20Ankle%20Ability%20Measure.pdf>

The [Short Musculoskeletal Function Assessment](#) (SMFA) questionnaire can be used with several types of musculoskeletal injuries, is comparable to other assessment scales such as the FAAM, and is freely available.<sup>39-41</sup> <sup>l</sup>

The [PROMIS scale](#) (Patient-Reported Outcomes Measurement Information System) measures function in lower extremities using computer-assisted technology. Having been integrated into the Epic electronic medical record software, the PROMIS scale has been validated in multiple settings.<sup>42-44</sup> <sup>m</sup>

## VI. Specific Conditions and Surgical Procedures

### A. Ankle Arthroscopy and Cheilectomy

Not counting arthroscopic approaches to other surgical procedures, arthroscopy for removing a loose body is a covered procedure when there is evidence of the ankle catching and/or locking and/or effusion (presence of joint fluid and swelling). Arthroscopy, for removing bone spurs (cheilectomy), is also a covered procedure when there is evidence of bony impingement. A 2015 systematic review reported good clinical outcomes in 64-100% of patients undergoing arthroscopic treatment for anterior ankle impingement, with complications seen in only 5% of cases.<sup>45</sup> The same review also found that good to excellent patient satisfaction was seen in 74-100% of cases, and the lowest satisfaction was reported in studies with follow-up >5 years.<sup>45</sup>

### B. Ankle Arthrodesis/Fusion or Arthroplasty/Replacement

Work related ankle injuries can be sudden and traumatic. They can result from a crush injury; or start as a soft tissue injury, such as a sprain, and worsen over time if proper treatment is not provided at the start or if significant comorbidities exist. Ankle arthrodesis and ankle arthroplasty are both surgical options when the ankle cartilage is so damaged by arthritis that joint movement and weight bearing activities cause intolerable pain. Fusing the tibia, fibula, and talus (arthrodesis) or replacing the ankle joint (arthroplasty) are major procedures and require inpatient hospitalization and several weeks of protected weight bearing followed by a structured rehabilitation program. Full recovery generally takes several months. These procedures are usually reserved for advanced stages of impairment or disability when:

- Osteoarthritis has resulted in an unacceptable level of impairment in the performance of normal daily activities, or has created a disability that, without treatment, prevents gainful employment
- There are deformities (congenital or developmental) in the joint, and
- Prior conservative and surgical treatments have been unsuccessful in restoring function.

Determining whether arthrodesis or arthroplasty is preferable is a matter of clinical judgment. Generally, ankle arthrodesis can include a broader set of patients (e.g. with comorbidities) than arthroplasty, which requires more careful patient selection to achieve desirable outcomes.

<sup>l</sup> <https://www.ortho.umn.edu/research/mfa-smfa-resources>

<sup>m</sup> <http://www.healthmeasures.net/explore-measurement-systems/promis>

## Arthrodesis/Fusion

Arthrodesis is a permanent fusion of the tibia, fibula, and talus. The expected outcome is reduced or absent pain, but because fusion fixes the ankle in one position, it will no longer be able to move. All conservative measures should be exhausted before resorting to an arthrodesis. Risk factors to evaluate before deciding on a fusion include the availability of viable bone to support the fusion, adequate nerve and blood supply to allow healing, and deformities or problems from earlier injuries and treatments that could compromise the effectiveness of the surgery.<sup>46-49</sup>

In a systematic review, revision rates following ankle arthrodesis was found to be 9% (95% CI, 5.5% to 11.6%), with the primary reason for revision being nonunion (65%).<sup>50</sup> High-risk patients, including those with diabetes and obesity, may be at an even higher risk for nonunion and other complications. One study found that obese arthrodesis patients (BMI  $\geq 30$ ) had significantly increased risks of major and minor complications within 90 days of surgery.<sup>51</sup> A study of risk factors for nonunion following arthrodesis found that noninsulin dependent diabetic patients were 18.7 times more likely to have a malunion arthrodesis.<sup>52</sup>

## Arthroplasty/Joint Replacement

Arthroplasty replaces the entire ankle joint with a prosthetic implant. Similar to arthrodesis, all conservative measures should be exhausted before resorting to an ankle arthroplasty. Diabetes and obesity pose significant risks for post-surgical complications and treatment failure. Strong consideration should be given to alternative treatments (i.e. nonsurgical, arthrodesis) or deferring surgery until these risk factors are appropriately treated and optimized. One study found diabetic patients to have greater incidence of poor clinical outcomes, early-onset of osteolysis, and an overall negative impact on short to medium-term results.<sup>53</sup> Another study found diabetes to be independently associated with an increased risk of perioperative complications, discharge to a facility versus home, and a longer hospital stay.<sup>54</sup> Obese patients have been found to have significantly greater odds of implant failure by final follow-up (adjusted OR 2.8, 95% CI 1.04 -7.53), and lower functional outcome scores when compared to non-obese patients.<sup>55, 56</sup> Werner et.al found that obesity was associated with significantly increased rates of all complications, including revision (OR=1.6, 95% CI 1.2 - 2.2) after arthroplasty.<sup>51</sup>

As with any joint replacement, there is always the possibility of having to revise/replace the prosthesis. Patients <50 years of age are likely to have better clinical results and comparable complication and survivorship rates compared to those >50 years of age.<sup>57</sup> In a study of national revision rates using registry data for different implants, the average revision rate was 21.8% after 5 years, and 43.5% after 10 years.<sup>58</sup> Another study of registry data found that survival rates for total ankle replacement was 0.87 (95% CI, 0.82–0.91) at 5 years, and 0.81 (95% CI, 0.74–0.88) at 10 years.<sup>59</sup>

## C. Subtalar Arthrodesis

The subtalar joint is located just below the ankle joint between the talus bone and calcaneus (heel) bone. A subtalar arthrodesis or fusion is performed to relieve pain during movement of the subtalar joint, and is indicated when a work related injury results in post-traumatic arthritis of the hindfoot.<sup>60, 61</sup>

The hindfoot has several points of articulation with concave and convex curvatures, cavities, chambers, and canals. The ways in which these spaces and surfaces are shaped and positioned are not the same in everyone. The decision to fuse two or more joints depends on how severely a deformity produces instability and pain, and how likely it is that surgery will improve and relieve them. Correction of deformities helps to relieve symptoms and improve surgical prognosis and functionality.<sup>62</sup>

The subtalar joint enables the foot to adjust to uneven ground and rotates in multiple directions during walking and standing.<sup>63</sup> Arthrodesis of the subtalar joint (fusing the talus and calcaneus) can be done as a single stand-alone procedure, whereas a double (adding the talonavicular joint) and triple (adding the calcaneocuboid joint) arthrodesis are done *in addition to the subtalar fusion*.<sup>64</sup>

A double fusion preserves function of the midtarsal joint, is a simpler procedure, and avoids the risk of midtarsal nonunion or malunion.<sup>65</sup> The triple arthrodesis is usually reserved for correction of painful and deforming conditions e.g. tarsal coalition (abnormal connection of two normally separate bones), planovalgus (rigid flat foot), and cavovarus (high arch and inward turned heel) after conservative care has failed.<sup>64, 66, 67</sup>

#### D. Debridement or Stabilization of a Medial or Lateral Talar Lesion

Injuries may cause chondral (cartilage) or osteochondral (bone and cartilage) lesions (OCLs) affecting the tibia, fibula or talus. These defects may cause or aggravate degenerative conditions of the structures that comprise the joints of the ankle. Symptoms can present immediately following injury, or may appear later if a chronic degenerative process is present. Nearly all lateral OCLs have a history of trauma, whereas medial OCLs are less likely to result from a previous trauma.<sup>68</sup> There are no physical findings indicative of lateral OCLs.

Treatment of medial or lateral talar injuries is directed at stabilizing the ankle or restoring its functional anatomy. Depending upon the nature of the lesion(s), in each individual case, treatment may be non-surgical (e.g. immobilization, restricted weight bearing) or surgical (e.g. debridement, fixation, microfracture). Specific to the medial lesion, is the need to have a positive diagnostic lidocaine injection before surgery is considered to signify that surgery is likely to relieve pain.

A decision to proceed to surgery treatment should be made only after considering relative contraindications such as age, BMI, the extent of ankle trauma, and the presence of osteophytes. There appears to be a correlation between lesion properties and clinical outcome. A case series found that a lesion diameter of >15mm was correlated with worse clinical outcomes following microfracture, and a cohort study found that risk of clinical failure following marrow stimulation procedures was significantly associated with a defect area >150 mm<sup>2</sup>.<sup>69, 70</sup> A separate study found shoulder-type ankle lesions (uncontained lesions with no peripheral cartilage border) experienced worse clinical outcomes regardless of size or location.<sup>71</sup>

## E. Lateral Ligament Repair or Reconstruction

Lateral ankle ligament injuries are common, with one study finding that among 6 million patients, 3.2% reported lateral ankle ligament injury or instability.<sup>72</sup> Acute injuries from initial inversion and plantarflexion trauma may damage the lateral ligaments.<sup>73</sup> Chronic ankle instability can result if the injury is severe, left untreated, or is undertreated.<sup>74</sup>

Non-operative treatment such as rest, ice, compression, and elevation (RICE), functional treatment, or short-term immobilization, is generally the first choice for such injuries.<sup>75-78</sup> In most cases, non-operative care can lead to a fully functional recovery.<sup>73</sup>

When surgery is indicated, repair of the ligament using the patient's own tissue is generally considered the first line of treatment (e.g. Bröstrom procedure).<sup>79-81</sup> When there is insufficient tissue or if persistent laxity is present, reconstruction using an auto- or allograft, (e.g. Watson-Jones or Evans technique) should be considered.<sup>74, 81-83</sup> Studies have shown that lateral ankle instability treated by reconstruction, shows no significant difference in ankle plantarflexion or dorsiflexion ROM when compared with the contralateral extremity<sup>84</sup> While there is concern over excessive stiffness and decreased ankle inversion after reconstruction, the preservation of muscle strength allows for preservation of ankle eversion.<sup>83, 84</sup>

## F. Peroneal Tendon Repair

The peroneal tendons, including the peroneus brevis and peroneus longus tendons are common sources of tendon pathology in the ankle.<sup>85, 86</sup> The peroneal tendons can be traumatized with a single injury, or repeatedly over time by mechanisms such as acute inversion ankle sprains or peroneal subluxation.<sup>85-87</sup> Peroneal tendon disorders can present as posterolateral ankle pain, and may include tenosynovitis, tendon dislocation, subluxation, or rupture.<sup>88, 89</sup>

Anatomic features, such as a low-lying brevis muscle belly or a peroneus quartus may be contributing factors to peroneal tendon injury.<sup>90-93</sup> When considering repair for a work-related peroneal tendon injury and underlying deformities (e.g. pes cavus) are present, correction of the deformity at the time of surgery may be done if required for a successful surgical outcome.<sup>85, 86, 88, 94, 95</sup>

## G. Achilles Tendon Repair or Reconstruction

The Achilles tendon is the largest tendon in the body. Made up of fibrous connective tissue, it may become susceptible to injury over time due to routine body stressors, activity changes, and lack of blood flow to the area. In a study of 697 patients presenting to a clinic with a foot or ankle complaint, 5.6% of patients were found to have an Achilles tendinopathy.<sup>96</sup>

An Achilles tendon repair or reconstruction procedure is performed when injury causes a partial tear or acute rupture of the tendon attaching the calf muscles (soleus and gastrocnemius) to the heel bone (calcaneus). The ultimate goal of any Achilles tendon treatment is to have the ruptured ends of the tendon rejoined, and the tendon restored to its full length and function.

## Repair at Insertion

The clinical presentation of insertional Achilles tendinopathy includes pain in the back of the leg near the heel.<sup>97</sup> Some patients may present with a small lump right above the heel (Haglund's deformity).<sup>98</sup> Evidence suggests that both surgical and conservative treatments for insertional Achilles tendinopathy are effective.<sup>97, 99</sup> At least 12 weeks of conservative care, including activity modification, non-opioid analgesics, and/or immobilization with braces should be tried prior to any surgical intervention for insertional Achilles tendinopathy.<sup>99</sup> Corticosteroid injections are generally discouraged in treatment of Achilles tendinopathy. While some studies have shown short-term benefits, the adverse effects of corticosteroid injections such as atrophy, rupture, and decreased strength of the tendon, suppress any potential value.<sup>100</sup>

Surgical repair of the Achilles tendon at the calcaneal insertion point is done for inflammation of the sheath surrounding the tendon and the deterioration of the associated connective tissue.<sup>97, 101</sup> The damaged portion of the tendon is removed and, after preparing the heel bone surface, the healthy portion is reattached.

## Repair

The primary surgical procedure performed for acute ruptures of the Achilles tendon, an Achilles tendon repair, can be performed with the first instance of a combination of clinical findings. Clinical findings indicative of an Achilles repair include: acute rupture of the tendon, pain, swelling, positive Thompson's sign, plantarflexion weakness, and a palpable defect. Acute tears may be treated surgically or conservatively with functional rehabilitation. Conservative treatment appears to have a higher incidence of re-ruptures but avoids potential complications of surgery such as infections and wound healing complications.<sup>102, 103</sup>

## Reconstruction

Chronic Achilles tendon tears are more difficult to diagnosis as scarring may replace the palpable defect seen in acute tears. Due to retraction of the tendon, primary repair is not always feasible for chronic tears. A preoperative MRI is required to better define the anatomy of a chronic tear. Currently there is no gold standard for repairing chronic tears; but multiple options exist, such as: flap tissue turn down, local tendon transfer, autologous free tendon grafts, and allografts.<sup>104</sup>

## H. Posterior Tibialis Tendon Reconstruction

Posterior tibialis tendon insufficiency/dysfunction (PTTD) occurs when the posterior tibial tendon becomes inflamed or torn. The posterior tibialis attaches to the navicular on the medial aspect of the foot helping to support the arch. Diagnosis of PTTD is supported by the clinical findings of:

1. Swelling along the medial aspect of the foot and ankle,<sup>105</sup>
2. Changes in the shape of foot with gradual collapse of the medial arch and increasing hindfoot valgus,<sup>106</sup> and
3. Inability to do a single foot heel rise (stand of toes) due to pain and weakness.<sup>107</sup>

Conservative treatment prior to surgical intervention is highly effective, with a recent study showing 87.5% of patients achieving success with non-operative treatment.<sup>108</sup> If conservative treatment is not successful, posterior tibialis tendon reconstruction may be accomplished through a variety of surgical procedures such as:<sup>109-111</sup> gastrocnemius recession,<sup>111</sup> tenosynovectomy,<sup>112</sup> tendon transfer,<sup>113</sup> osteotomy,<sup>111, 114</sup> and arthrodesis/fusion.<sup>113</sup> The procedure of choice is determined by the severity and degree of tendon disease.<sup>111, 115</sup> Recovery after one of these procedures is likely to require 12 weeks of non-weight bearing.

### PTTD and Work-relatedness

As previously discussed in the Pre-existing Non-work related Conditions section, PTTD, or pes planus in adults, it is unlikely that cumulative weight bearing in the workplace would arise or worsen such a condition. The consensus of the guideline authors is that PTTD is closely correlated with genetic and congenital predisposition, and does not normally result from cumulative workplace exposure. In the patient with congenital hindfoot valgus and pes planus posture of the foot, PTTD is unlikely to arise from, or be worsened by cumulative weight bearing in the workplace. As such, PTTD is generally not considered an occupational disease.

## I. Tarsal Tunnel Release

Tarsal Tunnel Syndrome (TTS) occurs when systemic disease, injury, or body structure entraps or compresses the posterior tibial nerve or one of its branches (e.g. the lateral and medial plantar nerves). Examples include space-occupying lesions, fractures of the medial calcaneal wall, direct trauma to the heel, and traction neuritis.<sup>116</sup> TTS is a relatively rare condition, and other causes of medial ankle and plantar foot pain include but are not limited to plantar fasciitis, intervertebral disk lesion, interdigital neuroma, plantar fibromatosis, peripheral vascular disease, valgus hindfoot, rheumatoid arthritis, tenosynovitis, and diabetic neuropathy.<sup>117</sup> It is important to rule out etiologies that are more common prior to arriving upon the diagnosis of TTS. Care should be taken in patients with idiopathic or traumatic etiologies, as they have been shown to be associated with worse clinical outcomes following surgery.<sup>118</sup> Systemic comorbidities such as back pain, depression, COPD, or total previous systemic surgeries have also been shown to be associated with worse clinical outcomes.<sup>119</sup>

Tarsal tunnel release exposes the tibial nerve and removes anatomical structures causing the entrapment or compression. It is a covered procedure when all the following criteria are met:

1. A documented discrete work-related foot/ankle injury has occurred.
2. Presence of pain and/or paresthesias in the distribution of the medial and/or lateral plantar nerves.<sup>118</sup>
3. An MRI demonstrates a compressive lesion (e.g. a cyst) affecting the tibial nerve OR if there is no evidence of a compressive lesion, a positive nerve conduction study (NCS) consistent with tarsal tunnel syndrome.



A positive NCS consistent with tarsal tunnel syndrome is an acceptable diagnostic tool, as it has been found that NCS may be abnormal in some patients with suspected TTS.<sup>120</sup> A positive NCS will generally show a > 1msec difference between the terminal latency of the medial plantar nerve (MPN) to the abductor hallucis muscle and terminal latency of the lateral plantar nerve (LPN) to the abductor digiti quinti muscle. Normal findings of these terminal latencies are MPN of < 6.2msec and LPN of < 7 msec. Increases in these latencies and those of sensory nerve conduction velocities are also indicative of TTS.<sup>121</sup>

## J. Amputations

Amputation is a significant life-altering event. It should only be considered if the limb cannot be reconstructed and/or removal will help achieve the best possible outcome. An amputation may be necessary for preventing the spread of recalcitrant infections, severe peripheral vascular disease, persistent nonunion of bone, and when there is insufficient bone, muscle, or nerve for reconstruction. Amputation when pain is the primary indication is generally discouraged; see [Amputations Contemplated in the Setting of Chronic Pain](#).

Throughout treatment for lower limb injuries, patients should be monitored for risk factors that could lead to amputation. If all conservative care options have been exhausted and amputation is the only choice, the level of the planned amputation should be thoroughly evaluated for the limb's ability to heal and achieve maximum function. If the severity of risk factors and the potential for major complications such as deep wound infection and supplementary limb amputation outweigh the benefit of the planned procedure, delaying amputation until the risk factors have improved or proceeding with an alternative non-surgical treatment plan may be necessary. For example, consider consulting with an Orthotist and/or Prosthetist to evaluate the need for specialized ankle foot orthoses. One such device is the [Dynamic Offloading Brace](#), which has the potential to prevent amputations.<sup>n</sup>

### [Amputations Contemplated in the Setting of Chronic Pain](#)

The decision algorithm to proceed with a partial foot or lower limb amputation is complex and not within the scope of this guideline. Amputation for the purpose of intractable pain, however, is controversial and merits discussion. While cases are relatively infrequent, such amputations can result in significant morbidity, including continued pain. A recent study of patients with a diagnosis of Complex Regional Pain Syndrome (CRPS) found that 22% of patients undergoing amputations experienced postoperative complications, and 72% of patients experienced phantom limb pain within 3 months, increasing to 77% of patients at  $\geq 1$  year post amputation.<sup>122</sup>

While there is no absolute marker for the source of pain, every effort should be taken to ensure that a patient's pain correlates with the diagnosis, and that any proposed procedure is likely to effectively address the source of pain and increase the chance of improved functional outcomes. The provider should watch for the development of unresolved chronic pain or sudden changes in the type and level of pain,

---

<sup>n</sup><http://www.lni.wa.gov/ClaimsIns/Providers/TreatingPatients/ByCondition/CovMedDev/SpecCovDec/DynamicOffloadingBraces.asp>

and consult with any specialists needed to establish an effective pain management plan. If prescribing opioids are part of that plan, the prescriber should follow L&I's evidence based [Guideline for Prescribing Opioids to Treat Pain in Injured Workers](#).<sup>o</sup> When, as a last resort, amputation is being considered primarily for the purpose of reducing pain, the worker must be evaluated at [Labor & Industries designated Amputation Center of Excellence](#).<sup>p</sup>

## VII. Return to Work

Return to work (RTW) is expected after most occupational foot and ankle injuries. Duration of disability or time off work depend on many factors such as the severity of the injury, type of treatment, comorbid conditions, and job class type. Multiple resources are available through L&I's [RTW program](#) to help providers in their interactions with workers, employers, and claim managers to discuss and coordinate the best ways to help with return to work.<sup>q</sup> There is a particularly useful "[Return to Work Desk Reference](#)" for attending providers with guidance on how to talk with workers and their employers (and get paid for it), online publications to inform the patient how returning to work can reduce disability, descriptions of best practices, checklists, algorithms, vignettes, and a list of ways L&I staff can assist.<sup>r</sup>

L&I has also published a [Functional Recovery Interventions Tracking Sheet](#) that is designed as a checklist for engaging the patient in discussions of recovery and returning to work.<sup>s</sup>

---

<sup>o</sup> <http://www.lni.wa.gov/ClaimsIns/Files/OMD/MEDTreat/FINALOpioidGuideline010713.pdf>

<sup>p</sup> <http://www.uwmedicine.org/harborview/services/burn-center>

<sup>q</sup> <http://www.lni.wa.gov/ClaimsIns/Providers/TreatingPatients/RTW/default.asp>

<sup>r</sup> <http://www.lni.wa.gov/IPUB/200-002-000.pdf>

<sup>s</sup> <http://www.lni.wa.gov/forms/pdf/F245-420-000.pdf>

## VIII. Acknowledgements

Acknowledgement and gratitude go to all subcommittee members, clinical experts, consultants, and L&I staff who contributed to this important guideline:

### **IIMAC Committee Members**

Chris Howe, MD (Chair) – *Proliance Orthopedic Associates, Valley Medical Center*

Andrew Friedman, MD – *Virginia Mason Medical Center*

Kirk Harmon, MD – *MultiCare*

### **Subcommittee Clinical Experts**

Janna Friedly, MD – *Harborview Medical Center*

Jonathan Hall, MD – *ProOrtho, Proliance Surgeons*

Byron Hutchinson, DPM – *Franciscan Foot and Ankle Associates*

Anne McCormack, MD – *Providence Everett Healthcare*

Erik Novak, MD, PhD – *Proliance Orthopedic Associates, Valley Medical Center*

Bruce Sangeorzan, MD – *UW and Director VA Center for Limb Loss Prevention and Prosthetic Engineering*

Eugene Pepper Toomey, MD – *Swedish Hospital*

### **Qualis Health Consultants**

Shari Fowler-Koorn, RN

Ken O'Bara, MD

John Sparks, MD

Margaret Baker, MD

### **Labor and Industries Staff**

Gary M. Franklin, MD, MPH, Medical Director

Lee Glass, MD, JD, Associate Medical Director

Nicholas Reul, MD, MPH, Associate Medical Director

Zachary Gray, MPH, Epidemiologist

Simone P. Javaher, RN, BSN MPA, Clinical Manager of Health Policy

Angela Jones, BSN, RN

Aquila Doore, RN, BSN-BC, MBA, JD, Occupational Nurse Consultant

## IX. References

1. Bureau of Labor Statistics, *Number of nonfatal occupational injuries and illnesses requiring days away from work, 2014*, U.D.o. Labor, Editor. 2015: Washington, DC.
2. Lambers, K., D. Ootes, and D. Ring, *Incidence of patients with lower extremity injuries presenting to US emergency departments by anatomic region, disease category, and age*. Clin Orthop Relat Res, 2012. **470**(1): p. 284-90.
3. Walters, J.L. and S.S. Mendicino, *The flexible adult flatfoot: anatomy and pathomechanics*. Clin Podiatr Med Surg, 2014. **31**(3): p. 329-36.
4. Ozan, F., et al., *Symptomatic flexible flatfoot in adults: subtalar arthroereisis*. Therapeutics and clinical risk management, 2015. **11**: p. 1597.
5. Shibuya, N., et al., *Characteristics of adult flatfoot in the United States*. The Journal of foot and ankle surgery, 2010. **49**(4): p. 363-368.
6. Lee, M.S., et al., *Diagnosis and treatment of adult flatfoot*. J Foot Ankle Surg, 2005. **44**(2): p. 78-113.
7. Scharer, B.M., B.E. Black, and N. Sockrider, *Treatment of painful pediatric flatfoot with Maxwell-Brancheau subtalar arthroereisis implant a retrospective radiographic review*. Foot & ankle specialist, 2010. **3**(2): p. 67-72.
8. Brancheau, S.P., K.M. Walker, and D.R. Northcutt, *An analysis of outcomes after use of the Maxwell-Brancheau Arthroereisis implant*. The Journal of Foot and Ankle Surgery, 2012. **51**(1): p. 3-8.
9. Nelson, S.C., D.M. Haycock, and E.R. Little, *Flexible flatfoot treatment with arthroereisis: radiographic improvement and child health survey analysis*. The Journal of foot and ankle surgery, 2004. **43**(3): p. 144-155.
10. Abousayed, M.M., et al., *Classifications in Brief: Johnson and Strom Classification of Adult-acquired Flatfoot Deformity*. 2016, Springer.
11. Erol, K., et al., *An important cause of pes planus: the posterior tibial tendon dysfunction*. Clinics and practice, 2015. **5**(1).
12. Zaw, H. and J.D.F. Calder, *Operative management options for symptomatic flexible adult acquired flatfoot deformity: A review*. Knee Surgery, Sports Traumatology, Arthroscopy, 2010. **18**(2): p. 135-142.
13. McCulloch, J., *Health risks associated with prolonged standing*. Work, 2002. **19**(2): p. 201-205.
14. Burns, J., et al., *Interventions for the prevention and treatment of pes cavus*. The Cochrane Library, 2007.
15. Aminian, A. and B.J. Sangeorzan, *The anatomy of cavus foot deformity*. Foot and ankle clinics, 2008. **13**(2): p. 191-198.
16. Statler, T.K. and B.L. Tullis, *Pes cavus*. Journal of the American Podiatric Medical Association, 2005. **95**(1): p. 42-52.
17. Burns, J., et al., *The effect of pes cavus on foot pain and plantar pressure*. Clinical Biomechanics, 2005. **20**(9): p. 877-882.
18. Desai, S.N., R. Grierson, and A. Manoli, *The cavus foot in athletes: fundamentals of examination and treatment*. Operative Techniques in Sports Medicine, 2010. **18**(1): p. 27-33.
19. Manoli, A. and B. Graham, *The subtle cavus foot, "the underpronator," a review*. Foot & ankle international, 2005. **26**(3): p. 256-263.
20. Groner, T.W. and L.A. DiDomenico, *Midfoot osteotomies for the cavus foot*. Clinics in podiatric medicine and surgery, 2005. **22**(2): p. 247-264.

21. Zhou, Y., et al., *A prospective study of midfoot osteotomy combined with adjacent joint sparing internal fixation in treatment of rigid pes cavus deformity*. Journal of orthopaedic surgery and research, 2014. **9**(1): p. 44.
22. Irving, D.B., J.L. Cook, and H.B. Menz, *Factors associated with chronic plantar heel pain: a systematic review*. J Sci Med Sport, 2006. **9**(1-2): p. 11-22; discussion 23-4.
23. Cutts, S., et al., *Plantar fasciitis*. The Annals of The Royal College of Surgeons of England, 2012. **94**(8): p. 539-542.
24. Beeson, P., *Plantar fasciopathy: revisiting the risk factors*. Foot Ankle Surg, 2014. **20**(3): p. 160-5.
25. Waclawski, E.R., et al., *Systematic review: Plantar fasciitis and prolonged weight bearing*. Occupational Medicine, 2015. **65**(2): p. 97-106.
26. Riddle, D.L., et al., *Risk factors for Plantar fasciitis: a matched case-control study*. J Bone Joint Surg Am, 2003. **85-a**(5): p. 872-7.
27. Thomas, J.L., et al., *The diagnosis and treatment of heel pain: a clinical practice guideline—revision 2010*. The Journal of Foot and Ankle Surgery, 2010. **49**(3): p. S1-S19.
28. Rajput, B. and R.J. Abboud, *Common ignorance, major problem: the role of footwear in plantar fasciitis*. The Foot, 2004. **14**(4): p. 214-218.
29. Singh, D., et al., *Fortnightly review. Plantar fasciitis*. BMJ: British Medical Journal, 1997. **315**(7101): p. 172.
30. Orchard, J., *Plantar fasciitis*. Bmj, 2012. **345**: p. e6603.
31. Davis, P.F., E. Severud, and D.E. Baxter, *Painful heel syndrome: results of nonoperative treatment*. Foot & Ankle International, 1994. **15**(10): p. 531-535.
32. Woolf, A.D. and B. Pfleger, *Burden of major musculoskeletal conditions*. Bulletin of the World Health Organization, 2003. **81**(9): p. 646-656.
33. Peyron, J. and R. Altman, *The epidemiology of osteoarthritis*. Osteoarthritis. Diagnosis and Treatment. Philadelphia, PA: WB Saunders, 1984: p. 9-27.
34. Brown, T.D., et al., *Posttraumatic osteoarthritis: a first estimate of incidence, prevalence, and burden of disease*. J Orthop Trauma, 2006. **20**(10): p. 739-44.
35. Cushnaghan, J. and P. Dieppe, *Study of 500 patients with limb joint osteoarthritis. I. Analysis by age, sex, and distribution of symptomatic joint sites*. Annals of the rheumatic diseases, 1991. **50**(1): p. 8-13.
36. Wilson, M., et al. *Idiopathic symptomatic osteoarthritis of the hip and knee: a population-based incidence study*. in *Mayo Clinic proceedings*. 1990.
37. Young, C.C., et al., *Clinical examination of the foot and ankle*. Primary Care: Clinics in Office Practice, 2005. **32**(1): p. 105-132.
38. Martin, R.L., et al., *Evidence of validity for the Foot and Ankle Ability Measure (FAAM)*. Foot & Ankle International, 2005. **26**(11): p. 968-983.
39. Swiontkowski, M.F., et al., *Short musculoskeletal function assessment questionnaire: validity, reliability, and responsiveness*. The Journal of Bone & Joint Surgery, 1999. **81**(9): p. 1245-60.
40. Egol, K.A., et al., *Predictors of short-term functional outcome following ankle fracture surgery*. J Bone Joint Surg Am, 2006. **88**(5): p. 974-979.
41. Goldstein, C.L., et al., *Comparison of different outcome instruments following foot and ankle trauma*. Foot & ankle international, 2010. **31**(12): p. 1075-1080.
42. Cella, D., et al., *The Patient-Reported Outcomes Measurement Information System (PROMIS) developed and tested its first wave of adult self-reported health outcome item banks: 2005–2008*. Journal of clinical epidemiology, 2010. **63**(11): p. 1179-1194.

43. Liu, H., et al., *Representativeness of the patient-reported outcomes measurement information system internet panel*. Journal of clinical epidemiology, 2010. **63**(11): p. 1169-1178.
44. Rothrock, N.E., et al., *Relative to the general US population, chronic diseases are associated with poorer health-related quality of life as measured by the Patient-Reported Outcomes Measurement Information System (PROMIS)*. Journal of clinical epidemiology, 2010. **63**(11): p. 1195-1204.
45. Zwiers, R., et al., *Arthroscopic treatment for anterior ankle impingement: A systematic review of the current literature*. Arthroscopy - Journal of Arthroscopic and Related Surgery, 2015. **31**(8): p. 1585-1596.
46. Frey, C., et al., *A review of ankle arthrodesis: predisposing factors to nonunion*. Foot & Ankle International, 1994. **15**(11): p. 581-584.
47. Collman, D.R., M.H. Kaas, and J.M. Schuberth, *Arthroscopic ankle arthrodesis: factors influencing union in 39 consecutive patients*. Foot Ankle Int, 2006. **27**(12): p. 1079-85.
48. Saragas, N.P., *Results of arthroscopic arthrodesis of the ankle*. Foot and ankle surgery, 2004. **10**(3): p. 141-143.
49. DiGiovanni, C.W., et al., *The Importance of Sufficient Graft Material in Achieving Foot or Ankle Fusion*. J Bone Joint Surg Am, 2016. **98**(15): p. 1260-1267.
50. Haddad, S.L., et al., *Intermediate and long-term outcomes of total ankle arthroplasty and ankle arthrodesis. A systematic review of the literature*. J Bone Joint Surg Am, 2007. **89**(9): p. 1899-905.
51. Werner, B.C., et al., *Obesity Is Associated With Increased Complications After Operative Management of End-Stage Ankle Arthritis*. Foot Ankle Int, 2015. **36**(8): p. 863-70.
52. Chahal, J., et al., *Factors associated with outcome after subtalar arthrodesis*. J Orthop Trauma, 2006. **20**(8): p. 555-61.
53. Choi, W.J., et al., *The impact of diabetes on the short- to mid-term outcome of total ankle replacement*. Bone Joint J, 2014. **96-b**(12): p. 1674-80.
54. Schipper, O.N., et al., *Effect of diabetes mellitus on perioperative complications and hospital outcomes after ankle arthrodesis and total ankle arthroplasty*. Foot Ankle Int, 2015. **36**(3): p. 258-67.
55. Schipper, O.N., et al., *Effect of obesity on total ankle arthroplasty outcomes*. Foot and Ankle International, 2016. **37**(1): p. 1-7.
56. Gross, C.E., et al., *The Effect of Obesity on Functional Outcomes and Complications in Total Ankle Arthroplasty*. Foot Ankle Int, 2016. **37**(2): p. 137-41.
57. Rodrigues-Pinto, R., et al., *Total ankle replacement in patients under the age of 50. Should the indications be revised?* Foot Ankle Surg, 2013. **19**(4): p. 229-33.
58. Labek, G., et al., *Revision rates after total ankle arthroplasty in sample-based clinical studies and national registries*. Foot Ankle Int, 2011. **32**(8): p. 740-5.
59. Bartel, A.F. and T.S. Roukis, *Total Ankle Replacement Survival Rates Based on Kaplan-Meier Survival Analysis of National Joint Registry Data*. Clin Podiatr Med Surg, 2015. **32**(4): p. 483-94.
60. Vilá-Rico, J., et al., *Subtalar arthroscopic arthrodesis: Technique and outcomes*. Foot and Ankle Surgery, 2015.
61. Munoz, M.A., R. Augoyard, and F. Canovas, *Surgical treatment of hindfoot inflammatory diseases: 107 arthrodesis*. Orthopaedics and Traumatology: Surgery and Research, 2012. **98**(SUPPL. 6).
62. Chung, H.J., S.Y. Bae, and J.W. Choo, *Mid-term follow up results of subtalar distraction arthrodesis using a double bone-block for calcaneal malunion*. Yonsei Medical Journal, 2014. **55**(4): p. 1087-1094.

63. Beimers, L., *Subtalar joint kinematics and arthroscopy: insight in the subtalar joint range of motion and aspects of subtalar joint arthroscopy*. 2012.
64. Walter, R., S. Parsons, and I. Winson, *Arthroscopic Subtalar, Double, and Triple Fusion*. Foot and Ankle Clinics, 2016. **21**(3): p. 681-693.
65. Joveniaux, P., et al., *Long-term results of in situ subtalar arthrodesis*. International Orthopaedics, 2010. **34**(8): p. 1199-1205.
66. DeVries, J.G. and B. Scharer, *Hindfoot Deformity Corrected With Double Versus Triple Arthrodesis: Radiographic Comparison*. J Foot Ankle Surg, 2015. **54**(3): p. 424-7.
67. Lee, W.T., et al., *Instability of the Medial Column Post Triple Arthrodesis for Stage III Posterior Tibial Tendon Dysfunction*. Foot & Ankle Orthopaedics, 2016. **1**(1): p. 2473011416S00204.
68. Flick, A. and N. Gould, *Osteochondritis dissecans of the talus (transchondral fractures of the talus): review of the literature and new surgical approach for medial dome lesions*. Foot & ankle, 1985. **5**(4): p. 165-185.
69. Chuckpaiwong, B., E.M. Berkson, and G.H. Theodore, *Microfracture for osteochondral lesions of the ankle: outcome analysis and outcome predictors of 105 cases*. Arthroscopy: The Journal of Arthroscopic & Related Surgery, 2008. **24**(1): p. 106-112.
70. Choi, W.J., et al., *Osteochondral lesion of the talus: Is There a critical defect size for poor outcome?* American Journal of Sports Medicine, 2009. **37**(10): p. 1974-1980.
71. Choi, G.W., et al., *Osteochondral lesions of the talus: are there any differences between osteochondral and chondral types?* Am J Sports Med, 2013. **41**(3): p. 504-10.
72. Werner, B.C., et al., *Trends in Ankle Arthroscopy and Its Use in the Management of Pathologic Conditions of the Lateral Ankle in the United States: A National Database Study*. Arthroscopy, 2015. **31**(7): p. 1330-7.
73. Kerkhoffs, G.M., et al., *Surgical versus conservative treatment for acute injuries of the lateral ligament complex of the ankle in adults*. The Cochrane Library, 2007.
74. Shakked, R.J., S. Karnovsky, and M.C. Drakos, *Operative treatment of lateral ligament instability*. Curr Rev Musculoskelet Med, 2017. **10**(1): p. 113-121.
75. Verhagen, R.A.W., G. de Keizer, and C.N. van Dijk, *Long-term follow-up of inversion trauma of the ankle*. Archives of Orthopaedic and Trauma Surgery, 1995. **114**(2): p. 92-96.
76. Kerkhoffs, G.M., et al., *Immobilisation and functional treatment for acute lateral ankle ligament injuries in adults*. The cochrane library, 2002.
77. Kerkhoffs, G.M., et al., *Different functional treatment strategies for acute lateral ankle ligament injuries in adults*. The cochrane library, 2002.
78. Petersen, W., et al., *Treatment of acute ankle ligament injuries: a systematic review*. Archives of orthopaedic and trauma surgery, 2013. **133**(8): p. 1129-1141.
79. Broström, L., *Sprained ankles. VI. Surgical treatment of "chronic" ligament ruptures*. Acta chirurgica Scandinavica, 1966. **132**(5): p. 551.
80. Gould, N., D. Seligson, and J. Gassman, *Early and late repair of lateral ligament of the ankle*. Foot and Ankle, 1980. **1**(2): p. 84-89.
81. Baumhauer, J.F. and T. O'brien, *Surgical considerations in the treatment of ankle instability*. Journal of athletic training, 2002. **37**(4): p. 458.
82. Younes, C., et al., *Long-term results of surgical reconstruction for chronic lateral instability of the ankle: Comparison of watson-jones and evans techniques*. Journal of Trauma - Injury, Infection and Critical Care, 1988. **28**(9): p. 1330-1334.
83. Ventura, A., et al., *Lateral ligament reconstruction with allograft in patients with severe chronic ankle instability*. Archives of Orthopaedic and Trauma Surgery, 2014. **134**(2): p. 263-268.

84. Hsu, A.R., et al., *Intermediate and Long-Term Outcomes of the Modified Brostrom-Evans Procedure for Lateral Ankle Ligament Reconstruction*. *Foot Ankle Spec*, 2016. **9**(2): p. 131-9.
85. Cerrato, R.A. and J.T. Campbell, *Tenodesis and transfer procedures for peroneal tears and tendinosis*. *Techniques in Foot and Ankle Surgery*, 2009. **8**(3): p. 119-125.
86. Cerrato, R.A. and M.S. Myerson, *Peroneal tendon tears, surgical management and its complications*. *Foot Ankle Clin*, 2009. **14**(2): p. 299-312.
87. Dombek, M.F., et al., *Peroneal tendon tears: A retrospective review*. *Journal of Foot and Ankle Surgery*, 2003. **42**(5): p. 250-258.
88. Bojanić, I., et al., *Peroneal tendoscopy - more than just a solitary procedure: Case-series*. *Croatian Medical Journal*, 2015. **56**(1): p. 57-62.
89. Lee, S.J., et al., *Ultrasound and MRI of the peroneal tendons and associated pathology*. *Skeletal Radiol*, 2013. **42**(9): p. 1191-200.
90. Rosenberg, Z.S., et al., *MR features of longitudinal tears of the peroneus brevis tendon*. *AJR Am J Roentgenol*, 1997. **168**(1): p. 141-7.
91. Khoury, N.J., et al., *Peroneus longus and brevis tendon tears: MR imaging evaluation*. *Radiology*, 1996. **200**(3): p. 833-41.
92. Zammit, J. and D. Singh, *The peroneus quartus muscle*. *Bone & Joint Journal*, 2003. **85**(8): p. 1134-1137.
93. Freccero, D.M. and M.J. Berkowitz, *The relationship between tears of the peroneus brevis tendon and the distal extent of its muscle belly: an MRI study*. *Foot Ankle Int*, 2006. **27**(4): p. 236-9.
94. Vega, J., et al., *Tendoscopic procedure associated with peroneal tendons*. *Techniques in Foot and Ankle Surgery*, 2013. **12**(1): p. 39-48.
95. Vega, J., et al., *Tendoscopic groove deepening for chronic subluxation of the peroneal tendons*. *Foot Ankle Int*, 2013. **34**(6): p. 832-40.
96. Waldecker, U., G. Hofmann, and S. Drewitz, *Epidemiologic investigation of 1394 feet: coincidence of hindfoot malalignment and Achilles tendon disorders*. *Foot Ankle Surg*, 2012. **18**(2): p. 119-23.
97. Wiegnerinck, J.I., et al., *Treatment for insertional Achilles tendinopathy: a systematic review*. *Knee Surg Sports Traumatol Arthrosc*, 2013. **21**(6): p. 1345-55.
98. Schepsis, A.A., H. Jones, and A.L. Haas, *Achilles tendon disorders in athletes*. *American Journal of Sports Medicine*, 2002. **30**(2): p. 287-305.
99. Kearney, R. and M.L. Costa, *Insertional achilles tendinopathy management: a systematic review*. *Foot Ankle Int*, 2010. **31**(8): p. 689-94.
100. Li, H.-Y. and Y.-H. Hua, *Achilles Tendinopathy: Current Concepts about the Basic Science and Clinical Treatments*. *BioMed Research International*, 2016. **2016**.
101. van Dijk, C.N., et al., *Terminology for Achilles tendon related disorders*. *Knee Surg Sports Traumatol Arthrosc*, 2011. **19**(5): p. 835-41.
102. Wu, Y., et al., *Is surgical intervention more effective than non-surgical treatment for acute Achilles tendon rupture? A systematic review of overlapping meta-analyses*. *International Journal of Surgery*, 2016.
103. Erickson, B.J., et al., *Is operative treatment of achilles tendon ruptures superior to nonoperative treatment?: A systematic review of overlapping meta-analyses*. *Orthopaedic Journal of Sports Medicine*, 2015. **3**(4).
104. Maffulli, N., A.G. Via, and F. Oliva, *Chronic Achilles tendon disorders: tendinopathy and chronic rupture*. *Clinics in sports medicine*, 2015. **34**(4): p. 607-624.
105. Churchill, R.S. and J.J. Sferra, *Posterior tibial tendon insufficiency. Its Diagnosis, Management, and Treatment*. *Am J Orthop (Belle Mead NJ)*, 1998. **27**(5): p. 339-47.



106. Yao, K., T.X. Yang, and W.P. Yew, *Posterior Tibialis Tendon Dysfunction: Overview of Evaluation and Management*. Orthopedics, 2015. **38**(6): p. 385-391.
107. Laughlin, T., *Evaluation and management of posterior tibial tendon dysfunction*. Foot Ankle Quart, 2000. **13**(1): p. 1-9.
108. Nielsen, M.D., et al., *Nonoperative care for the treatment of adult-acquired flatfoot deformity*. J Foot Ankle Surg, 2011. **50**(3): p. 311-4.
109. Hentges, M.J., et al., *Procedure selection for the flexible adult acquired flatfoot deformity*. Clin Podiatr Med Surg, 2014. **31**(3): p. 363-79.
110. Marks, R.M., et al., *Surgical reconstruction of posterior tibial tendon dysfunction: prospective comparison of flexor digitorum longus substitution combined with lateral column lengthening or medial displacement calcaneal osteotomy*. Gait Posture, 2009. **29**(1): p. 17-22.
111. Coetzee, J.C. and M.D. Castro, *The indications and biomechanical rationale for various hindfoot procedures in the treatment of posterior tibialis tendon dysfunction*. Foot and Ankle Clinics, 2003. **8**(3): p. 453-459.
112. Teasdall, R.D. and K.A. Johnson, *Surgical Treatment of Stage I Posterior Tibial Tendon Dysfunction*. Foot & Ankle International, 1994. **15**(12): p. 646-648.
113. Van Gestel, L., S. Van Bouwel, and J. Somville, *Surgical treatment of the adult acquired flexible flatfoot*. Acta Orthop Belg, 2015. **81**(2): p. 172-83.
114. Myerson, M.S., A. Badekas, and L.C. Schon, *Treatment of stage II posterior tibial tendon deficiency with flexor digitorum longus tendon transfer and calcaneal osteotomy*. Foot Ankle Int, 2004. **25**(7): p. 445-50.
115. Johnson, K.A. and D.E. Strom, *Tibialis posterior tendon dysfunction*. Clinical Orthopaedics and Related Research, 1989(239): p. 196-206.
116. Gould, J.S., *Tarsal tunnel syndrome*. Foot Ankle Clin, 2011. **16**(2): p. 275-86.
117. McSweeney, S.C. and M. Cichero, *Tarsal tunnel syndrome-A narrative literature review*. Foot (Edinb), 2015. **25**(4): p. 244-50.
118. Takakura, Y., et al., *Tarsal tunnel syndrome. Causes and results of operative treatment*. J Bone Joint Surg Br, 1991. **73**(1): p. 125-8.
119. Gondring, W.H., B. Shields, and S. Wenger, *An outcomes analysis of surgical treatment of tarsal tunnel syndrome*. Foot and Ankle International, 2003. **24**(7): p. 545-550.
120. Patel, A.T., et al., *Usefulness of electrodiagnostic techniques in the evaluation of suspected tarsal tunnel syndrome: An evidence-based review*. Muscle & nerve, 2005. **32**(2): p. 236-240.
121. Coughlin, M.J., C.L. Saltzman, and R.A. Mann, *Disorders of the Nerves*, in *Mann's Surgery of the Foot and Ankle*. 2013, Elsevier Health Sciences.
122. Bodde, M.I., et al., *Informed decision-making regarding amputation for complex regional pain syndrome type I*. J Bone Joint Surg Am, 2014. **96**(11): p. 930-934.