

Work-related Facet Neurotomy Guideline

June 2016

TABLE OF CONTENTS

I.	REVIEW CRITERIA FOR FACET NEUROTOMY—CERVICAL AND LUMBAR	1
II.	INTRODUCTION	3
III.	DOCUMENTATION OF EFFECTIVENESS	3
	For diagnostic blocks:	3
	For facet neurotomy:	4
	For repeat facet neurotomy:	4
IV.	PRE AND POST-NEUROTOMY PLANNING AND RETURN TO WORK	4
V.	LIMITATIONS TO COVERAGE	4
VI.	MEASURING FUNCTIONAL IMPROVEMENT	5
VII.	FACET NEUROTOMY PAIN RELIEF DIARY	6
	Pain Relief Diary (Form)	7
VIII.	REFERENCES	8

I. REVIEW CRITERIA FOR FACET NEUROTOMY—CERVICAL AND LUMBAR

A request may be appropriate for	If the patient has	AND the diagnosis is supported by these clinical findings		AND this has been done (if recommended)
Procedure	Diagnosis	Subjective/Objective	Diagnostic tests	Conservative care
<p>Cervical facet neurotomy--- Limited to C3-4 through C 6-7</p> <p>*One joint per each intervention (unilateral), with documented, clinically meaningful improvement in function* before further neurotomy at any level</p> <p>*see p. 6 of guideline</p>	<p>Cervical pain that meets these criteria:</p> <ul style="list-style-type: none"> • Is non-radicular, • Has lasted at least 6 months, • Can be referred to the facet joint, • Is unresponsive to other therapies including conservative care <p>AND</p> <ul style="list-style-type: none"> • There are no other clear structural causes of neck pain, and • There is no other pain syndrome affecting the spine <p>AND</p> <p>The patient is over 17 years of age</p>	<p>Segmental pain or tenderness at the level of the potentially involved unilateral facet joint</p> <p>AND</p> <p>The region involved is neurologically intact or if not, address the deficit in the treatment plan</p>	<p>Diagnostic imaging (e.g. CT, MRI) as needed to rule out any correctable structural lesion</p> <p>AND</p> <p>Two separate diagnostic medial branch blocks:</p> <ol style="list-style-type: none"> 1. One short-acting, low-volume (≤ 0.5 ml) local anesthetic 2. One long-acting, low-volume (≤ 0.5 ml) local anesthetic <p>Each block must be done with a single agent; a block combining short and long acting anesthetics cannot be approved. A placebo block may also be used. Do not use steroids with the anesthetic blocks.</p> <p>AND</p> <p>Documented COMPLETE (100%) relief of pain with EACH block.</p> <ul style="list-style-type: none"> • Documentation of pain relief should be a patient-generated report in real time, every 15 minutes for the first six hours following the block. The documentation tool is included in this guideline (FACET NEUROTOMY PAIN RELIEF DIARY) • Duration of pain relief should be consistent with the expected duration of the local anesthetic injected. 	<p>At least 6 months of conservative treatment, including for example:</p> <ul style="list-style-type: none"> • Physical therapy • Medications • Manual therapy (mobilization or manipulation)

A request may be appropriate for	If the patient has	AND the diagnosis is supported by these clinical findings		AND this has been done (if recommended)
Procedure	Diagnosis	Subjective/Objective	Diagnostic tests	Conservative care
<p>Lumbar facet neurotomy</p> <p>One or two joints (2 unilateral or 1 bilateral) per each intervention, with documented, clinically meaningful improvement in function* before further neurotomy at any level</p> <p>*see p. 6 of guideline</p>	<p>Low back pain that:</p> <ul style="list-style-type: none"> • Is non-radicular <p style="text-align: center;">AND</p> <ul style="list-style-type: none"> • Has lasted at least 6 months <p style="text-align: center;">AND</p> <ul style="list-style-type: none"> • Can be referred to the facet joint <p style="text-align: center;">AND</p> <ul style="list-style-type: none"> • Is unresponsive to other therapies including conservative care <p style="text-align: center;">AND</p> <ul style="list-style-type: none"> • There are no other clear structural causes of back pain • There is no other pain syndrome affecting the spine <p style="text-align: center;">AND</p> <p>The patient is over 17 years of age</p>	<p>Segmental pain or tenderness at the level of the potentially involved unilateral facet joint</p> <p style="text-align: center;">AND</p> <p>The region involved is neurologically intact or if not, address the deficit in the treatment plan</p>	<p>Diagnostic imaging (CT, MRI) as needed to rule out any correctable structural lesion</p> <p style="text-align: center;">AND</p> <p>Two different diagnostic medial branch blocks:</p> <ol style="list-style-type: none"> 1) One short-acting, low-volume (≤ 0.5 ml) local anesthetic 2) One long-acting, low-volume (≤ 0.5 ml) local anesthetic <p>A placebo block may also be used. Steroids should not be used with the anesthetic blocks.</p> <p style="text-align: center;">AND</p> <p>Documented relief of at least 80% of pain with each block.</p> <ul style="list-style-type: none"> • Documentation of pain relief should be a patient-generated report in real time, every 15 minutes for the first six hours following the block. The documentation tool is included in this guideline (FACET NEUROTOMY PAIN RELIEF DIARY). • Duration of pain relief should be consistent with the expected duration of the local anesthetic injected. 	<p>At least 6 months of conservative treatment, including for example:</p> <ul style="list-style-type: none"> • Physical therapy • Medications • Manual therapy (mobilization/manipulation)
<p>Neurotomy will not be approved without worker-generated, real time pain diary documentation of the effectiveness of the medial branch blocks, using the FACET NEUROTOMY PAIN RELIEF DIARY.</p>				

II. INTRODUCTION

The Department of Labor and Industries first published a guideline for facet neurotomy in August 2005. The original guideline was created by staff in the Office of the Medical Director, in consultation with practicing medical experts, based on the best scientific literature available. Randomized, double blind control trials on facet neurotomy in the treatment of cervical or lumbar facet (zygapophyseal) pain were reviewed. Strict adherence to established inclusion and exclusion criteria led to the selection of individuals with a clear diagnosis of medial branch-mediated nerve pain that may benefit from a facet neurotomy. The literature all had consistent conclusions:

- 1) A comprehensive physical exam and diagnostic workup is essential to exclude any reversible, structural pathology that could be the cause of the reported pain;
- 2) Diagnostic medial branch nerve blocks were given using not more than 0.5 ml of either a short-acting or long-acting anesthetic; and
- 3) Documentation of pain relief following each block corresponded to the expected duration of the local anesthetic injected.

This guideline complies with the facet neurotomy decision made by the Washington State Health Care Authority's Health Technology Assessment Program, May 2014. For the complete decision, see <http://www.hca.wa.gov/about-hca/health-technology-assessment/health-technology-reviews>.

III. DOCUMENTATION OF EFFECTIVENESS

For diagnostic blocks:

No pain medication, including IV analgesia, should be taken for four hours prior to or during each diagnostic medial branch nerve block. Conscious sedation should not be administered before or during a diagnostic block except in an extreme case of anxiety. Prior to the block, pain should be reproducible with positioning of the patient, to at least a "4" on a 0-10 pain scale.

After each diagnostic block, the injured worker must document the level of pain relief obtained using the [FACET NEUROTOMY PAIN RELIEF DIARY](#) found in this guideline (it may be copied as needed). The worker is to remain in the clinic area for at least 30 minutes after administration of the block. Then, the patient is to engage in the activities that previously produced pain and document the level of pain relief obtained every 15 minutes for a minimum of six hours following each block, or until their usual level of pain returns, whichever occurs first. The worker is to return the completed form to the physician at the next scheduled office visit. Place a copy of the Pain Relief Diary in the medical record, send a copy to the department or self-insurer, and another copy to the department's utilization review vendor if a facet neurotomy is to be requested.

Facet neurotomy will NOT be approved unless the Pain Relief Diary is submitted after each medial branch block.

For facet neurotomy:

If the diagnostic blocks are successful (as described in criteria table), and a facet neurotomy is approved, the provider and the patient should continue to document improvement in function and pain. Providers should use a valid and standardized assessment tool that emphasizes functional measures. One example of such a tool, the [Two-item graded chronic pain scale](#). Validated scales that are specific to the cervical or lumbar regions may also be used.

For repeat facet neurotomy:

Repeat facet neurotomy will not be authorized unless there is clear documentation that:

- More than 180 days has elapsed since the preceding facet neurotomy was performed; and
- The preceding facet neurotomy produced clinically meaningful improvement in function; and
- The clinically meaningful improvement in function was associated with rehabilitative benefits, such as enabling the worker to participate in vocational rehabilitation, to successfully complete a work-hardening program, or to engage in other activities that assist the worker in improving physical or vocational functioning in an on-going manner; and
- All the guideline criteria are met, and
- The worker is not at maximum medical improvement; and
- The request has undergone utilization review.

IV. PRE AND POST-NEUROTOMY PLANNING AND RETURN TO WORK

Prior to a facet neurotomy, a formal plan for reactivation must be developed and agreed upon by the patient and the provider. Vocational assessment and/or plan development should be considered prior to the procedure. Since facet neurotomy is done only after other treatments have failed to provide sufficient benefit, the worker may be determined to be at maximum medical improvement after the procedure.

Progressive reactivation, as appropriate based on the injured worker's condition, may include up to four weeks of outpatient physical therapy or occupational therapy, home exercise program, or work hardening. The ultimate goal is to return to a pre-injury level of functioning and a return to work.

V. LIMITATIONS TO COVERAGE

The following procedures will not be covered:

- Facet neurotomy above C3
- Facet neurotomy for the thoracic spine
- Sacral or SI joint neurotomy
- Dorsal rhizotomy
- Facet neurotomy for headache
- Dorsal root ganglionectomy
- Transection or avulsion of other extradural spinal nerves
- Repeat neurotomy except under rare circumstances; see above.

VI. MEASURING FUNCTIONAL IMPROVEMENT

Effective facet neurotomy should result in clinically meaningful improvement in function. Providers should track function and pain on a regular basis, using the same validated tools at each visit, to determine the effect of their treatments. Documentation of improved function, meaning an improvement of at least 30%, is required for a repeat neurotomy to be considered. Injury-specific assessment tools, such as the neck disability index for cervical pain, have often been used to measure effectiveness of treatments. Generalized disability scales such as the Oswestry Disability Index, are also familiar to providers and relatively easy to use. Regardless of the assessment tool used, pain and functional improvement should be documented regularly and consistently.

One way to measure improvement in function is with the two-item graded chronic pain scale.

Two-item graded chronic pain scale ^[8]

Graded chronic pain scale: a two-item tool to assess pain intensity and pain interference										
<p>In the last month, on average, how would you rate your pain? Use a scale from 0 to 10, where 0 is "no pain" and 10 is "pain as bad as could be"? <i>[That is, your usual pain at times you were in pain.]</i></p>										
No pain						Pain as bad as could be				
0	1	2	3	4	5	6	7	8	9	10
<p>In the last month, how much has pain interfered with your daily activities? Use a scale from 0 to 10, where 0 is "no interference" and 10 is "unable to carry on any activities."</p>										
No interference						Unable to carry on any activities				
0	1	2	3	4	5	6	7	8	9	10

Interpretation of the Two Item Graded Chronic Pain Scale – This two item version of the Graded Chronic Pain Scale is intended for brief and simple assessment of pain severity in primary care settings. Based on prior research, the interpretation of scores on these items is as follows:

Pain Rating Item	Mild	Moderate	Severe
Average/Usual Pain Intensity	1–4	5–6	7–10
Pain-related interference with activities	1–3	4–6	7–10



Although pain intensity and pain-related interference with activities are highly correlated and tend to change together, it is recommended that change over time be tracked for pain intensity and pain-related interference with activities separately when using these two items.

For an individual patient, a reduction in pain intensity and improvement in pain-related interference with activities of two points is considered moderate but clinically significant improvement.

Similar pain ratings have been widely used in the Brief Pain Inventory, the Multidimensional Pain Inventory, and the Pain Severity Scale of the SF-12.

There is extensive research on the reliability, validity and responsiveness to change of these pain severity ratings, which is summarized in the following reference:

Von Korff, M., *Assessment of chronic pain in epidemiological and health services research: Empirical bases and new directions*, in *Handbook of Pain Assessment Third Edition*, D.C. Turk and R. Melzack, Editors. 2011, Guilford Press: New York. p. 455-473.

VII. FACET NEUROTOMY PAIN RELIEF DIARY

The administration of medial branch blocks requires technical expertise as well as thorough planning to evaluate and measure its effect. It is essential that the provider requesting the block work with the interventionist and explain to the patient the importance of completing the *Pain Relief Diary* per the requirements. The provider **is required** to complete the *Pain Relief Diary* (found on the following page) to document a successful medial branch block and send it to utilization review so they can evaluate whether to approve the request for a facet neurotomy.

Pain diary form is on the next page.

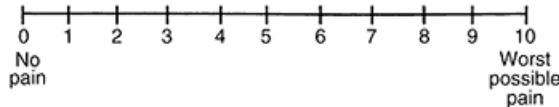
Pain Relief Diary (Form)

Name: _____ Claim # _____

Date of block: _____ Time of block: _____

Instructions for the patient and provider: **You MUST complete and submit this form in order to have a facet neurotomy considered for approval.** Complete the form in “real time” following the administration of a facet block. Pain relief level should be recorded while doing activities that previously caused pain.

Using the scale below, document the degree of pain intensity every 15 minutes starting at the time the block was given. Continue to document pain in the appropriate time frame **every fifteen minutes for a full 6 hours** following the block.



Pain level before block: _____ **Date/time of last pain medication** _____

	Pain level 0-10, where 0=no pain and 10=worst possible pain		Pain level 0-10, where 0=no pain and 10=worst possible pain
15 minutes after block		3 hr 15 min	
30 minutes		3 hr 30 min	
45 minutes		3 hr 45 min	
1 hour		4 hours	
1 hr 15 min		4 hr 15 min	
1 hr 30 min		4 hr 30 min	
1 hr 45 min		4 hr 45 min	
2 hours		5 hours	
2 hr 15 min		5 hr 15 min	
2 hr 30 min		5 hr 30 min	
2 hr 45 min		5 hr 45 min	
3 hours		6 hours	

VIII. REFERENCES

1. Van Kleef M, Barendse G, Kessels A, Voets H, Weber W. Randomized trial of radiofrequency lumbar facet denervation for chronic low back pain. *Spine* 1999;24:1937-1942.
2. Lord S, Barnsley L, Wallis B, McDonald G, Bogduk N. Percutaneous radiofrequency neurotomy for chronic cervical zygapophyseal joint pain. *N Engl J Med* 1996;335:1721-1726.
3. Niemisto L, Kalso E, Malmivaara A, Seitsalo S, Hurri H. Radiofrequency denervation for neck and back pain. A systematic review of randomized controlled trials (Cochrane Review). *The Cochrane Library* 2003;1.
4. Dreyfuss P, Halbrook B, Pauza K, Joshi A, McLarty J, Bogduk N. Efficacy and validity of radiofrequency neurotomy for chronic lumbar zygapophysial joint pain. *Spine* 2000;25:1270-1277.
5. Barlocher C, Krauss J, Seiler R. Kryorhizotomy: an alternative technique for lumbar medial branch rhizotomy in lumbar facet syndrome. *J. Neurosurg: Spine* 2003;98:14-20.
6. Wetzel F, Phillips F, Aprill C, Bernard T, LaRocca H. Extradural sensory rhizotomy in the management of chronic lumbar radiculopathy. *Spine* 1997;22:2283-2291.
7. Stovner L, Kolstad F, Helde G. Radiofrequency denervation of facet joints C2-C6 in cervicogenic headache: a randomized, double-blind, sham-controlled study. *Cephalalgia* 2004;24:821-830.
8. Turk, D.C. and R. Melzack, *Handbook of pain assessment*. 2011: Guilford Press.